



Review Of Retinal Microaneurysm Detection Methods For Automated Diagnosis Of Diabetic Retinopathy

Deepashree Devaraj

Assistant Professor, Instrumentation Technology Department, RVCE Bangalore, India

Nagaveena

M.Tech Student, BMSP&I, Instrumentation Technology Department, RVCE
Bangalore, India

Abstract:

Microaneurysm in the retina is one of the early signs of diabetic retinopathy. The recognition of Microaneurysms is an essential and the most challenging tasks for reliable automatic detection and diagnosis of diabetic retinopathy. This helps ophthalmologist to detect the emergence of its early symptoms and determine the next action step for the patient. A number of studies have been investigated on retinal FUNDUS images for diabetic retinopathy. This paper deals with the recently introduced methods for analyzing the microaneurysms detection, available for automated diagnosis. Although many algorithms have been developed, the accurate detection of microaneurysm in color retinal images is still a challenging problem. Automating this task, which is currently performed manually, would bring more objectivity and reproducibility.

Key words: FUNDUS image, diabetic retinopathy (DR), microaneurysm, non-proliferative diabetic retinopathy (NPDR) and proliferative diabetic retinopathy (PDR).

1.Introduction

The diabetes affects the blood vessels throughout the body including kidneys and eyes. The long term diabetes can cause irreversible preventable severe eye disease called diabetic retinopathy. Diabetic retinopathy results when diabetes affects blood vessels in the eyes, producing abnormalities such as micro aneurysms, haemorrhages, exudates and new blood vessels. This can cause loss of vision and even blindness.

These abnormalities are divided into two stages non-proliferative diabetic retinopathy (NPDR) and proliferative diabetic retinopathy (PDR). Non-proliferative diabetic retinopathy can be further classified as Mild NPDR, Moderate NPDR and Severe NPDR. Mild NPDR is characterized by the presence of at least one micro aneurysm. Moderate NPDR is characterized by the presence of haemorrhages, more micro aneurysms, soft exudates and venous beading. Severe NPDR has more haemorrhages, more micro aneurysms and micro vascular abnormalities. PDR is an advanced stage. In PDR the signals sent by the retina for nourishment trigger the growth of new blood vessels. This may in turn cause neovascularisation of disc and it may result in severe vision loss and even blindness.

Since the ratio of people afflicted with diabetic to the number of ophthalmologists is very high[1] there is a limits on the current diabetic retinopathy screening capabilities. Because the process of analyzing all retinal FUNDUS images is time consuming and repetitive. Many of these images may not have any abnormalities. Thus the requirement of the automating grading process by which more patients can be screened and if require can be sent to ophthalmologist for further examination. Several automated techniques are designed for diabetic retinopathy screening. In this paper, few recent microaneurysms detection methods for automated diagnosis of diabetic retinopathy are reviewed.

The presence of microaneurysms is considered as early stage of diabetic retinopathy. As shown in the fig.1, microaneurysms on the retina appear as small red dots of maximum diameter to be less than the diameter of the major optic veins. The recognition of microaneurysms is essential in the process of diabetic retinopathy grading, since it forms the basis of deciding whether an image of a patient's eye should be considered healthy or not.

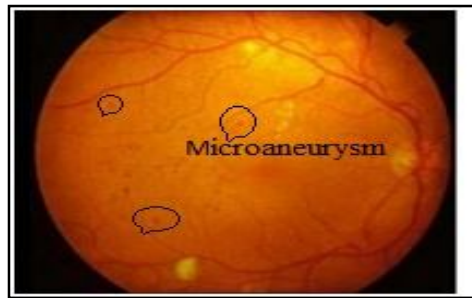


Figure 1: Retinal image with microaneurysm marked

The paper is organized as follows. Section I, II and III reviews three methodologies namely double-ring filter method, local rotating cross-section profile analysis and an ensemble-based framework, respectively. Section IV presents conclusion of these three methods.

2.Double-Ring Filter Method [1]

The first method discussed here is the double-ring filter method. In this method after image pre-processing, candidate regions for microaneurysms were detected using a double-ring filter. Any potential false positives located in the regions corresponding to blood vessels were removed by automatic extraction of blood vessels from the images. One hundred twenty six image features were determined and 28 components were selected by using principal component analysis. The candidate lesions were classified into microaneurysms or false positives using the rule-based method and an artificial neural network.

Retinopathy Online Challenge (ROC) database were used in this study. The database includes 50 retinal FUNDUS images with "gold standard" locations of microaneurysms identified by a consensus of four ophthalmologists. The ROC also includes 50 testing cases in which "gold standard" locations are not provided to the participants.

In this method first, images were pre-processed to reduce noise and variation in the brightness, using gamma correction and histogram expansion [4]. The contrast of microaneurysms tends to be high in green color, therefore, RGB color images were converted to green-channeled images. A low-pass filter based on FFT Fourier Transform) was applied for reducing image noise appeared after green channel extraction.

Microaneurysms appear as lesions darker than the surrounding retinal regions. The initial detection of the microaneurysms was attempted by applying the double-ring filter[5] on the green channel of the color images. This compares the target pixel values with the neighbouring pixel values. The filter consists of an inner circle and an outer ring with diameters of 5 and 13 pixels, respectively. An inner circle is defined as a region A. A rim width of outer ring is 2 pixels, and it is defined as a region C. A region B is a gap with 2 pixels widths, which is not used for filtering because this region is affected by a microaneurysm edges. The output value of this filter is as follows:

$$FA(x, y) = 128 - (k(x, y) - mA(x, y))$$

Where mA is mean in a region A and k(x,y) is a pixel value of p% of a histogram in a region C. If the FA was high, the pixel in question became a candidate pixel for microaneurysms. In this study, the maximum number of candidate lesions for microaneurysms in each image was limited to 275.

After the initial detection of microaneurysms, many blood vessels appeared as false positive in the pre-processed green-channeled images. In order to eliminate these false positives, the pixels corresponding to the part of the blood vessels were extracted by using the method, combined with double-ring filter and black-top-hat-transform [6]. The shapes of candidate lesions after the initial detection are affected by the structure of the double ring filter. Therefore, the shapes of candidate lesions were not determined accurately, which could influence the accuracy of image feature analysis. In order to determine the shapes of candidate lesions correctly, their shapes were re-examined. Finally, the candidate lesions were classified as microaneurysms or false positives by the rule-based method and by using an artificial neural network (ANN).

3.Local Rotating Cross-Section Profile Analysis [2]

The proposed method realizes Microaneurysm detection through the analysis of directional cross-section profiles, centered on the local maximum pixels of the pre-processed image. Then peak detection is applied on each profile and a set of attributes regarding the size, height, and shape of the peak are calculated subsequently. The statistical measures of these attribute values, as the orientation of the cross-section changes, constitute the feature set. This feature set is used in a Bayes classification to exclude spurious candidates.

The main input of the proposed method is the inverted green channel of a FUNDUS image. In this inverted green channel of a FUNDUS image the microaneurysms, hemorrhages and the vasculature will appear as bright structures and are local intensity maximum regions. Also consider the binary region of interest (ROI) mask [7] of image for detection. First image is pre-processed and then microaneurysms are detected by local intensity maximum structures on the pre-processed retinal image, usually with a Gaussian like intensity distribution. This means that every Microaneurysm region contains at least one regional maximum. A local maximum region (LMR) of a grayscale (intensity) image is a connected component of pixels with a given constant intensity value, such that every neighboring pixel of the region has a strictly lower intensity [8]. Therefore, it is sufficient to consider only the LMRs of the pre-processed image as possible microaneurysm candidate regions. In this implementation, simple breadth-first search algorithm is applied for the calculation of grayscale morphological reconstruction. Pixels of the image are processed sequentially, and compared to their 8-neighbours. If all neighbours have a lower intensity, then the pixel itself is a LMR. If there is a neighbouring pixel with higher intensity, then the current pixel may not be a maximum. A pixel is considered to be a possible maximum if all neighboring pixels have lower or the same intensity, in which case pixels with the same intensity are stored in a queue, and tested in the same way. If eventually the queue is emptied so that all the pixels it contained proved to be possible maxima, then the corresponding connected component is a LMR. Pixels of a LMR are considered individually as possible candidates, and the pixel with the maximum final score will represent the region.

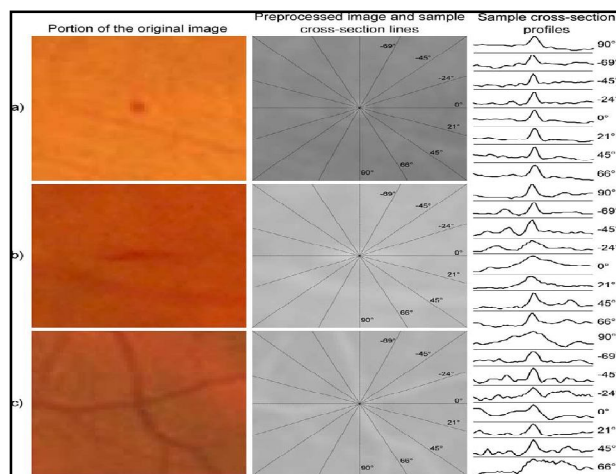


Figure 2: (a) Sample cross-section profiles of an microaneurysm (b) an elongated non-microaneurysm object (c) vessel crossing.

To examine the surrounding of a single maximum pixel in a microaneurysm candidate region, the intensity values along discrete line segments of different orientations, whose central pixel is the candidate pixel, are recorded. In this way a set of cross-sectional intensity profiles are obtained. Fig. 2 shows sample cross sections of an microaneurysm, an elongated non- microaneurysm structure and a vessel crossing. The orientations of the sample cross sections were chosen so that the differences between the objects are best shown. As it can be seen, microaneurysms show a definite Gaussian like peak for all directions, opposed to other noncircular structures.

On the obtained cross-section profiles, perform a peak detection step. To decide whether a peak is present at the center of the profile, i.e., at the location of the candidate point for a specific direction. Calculate several properties of the peak. The final feature set consists of a set of statistical measures that shows how these values vary as the orientation of the cross-section is changing. This way, the variation of important characteristics, such as symmetry and shape of the structure, and its difference from the background may be numerically expressed. This detects microaneurysms. Then Bayes classifier is used for classifying negative and positive microaneurysms.

4.An Ensemble-Based Framework[3]

An ensemble-based framework improves microaneurysm detection. This method is combination of internal components of microaneurysm detectors, namely pre-processing methods and candidate extractors. In the following paragraphs few pre-processing methods and candidate extractors are briefly explained. An ensemble-based framework uses any of these two combinations.

The pre-processing method Walter–Klein Contrast Enhancement [9] is used to enhance the contrast of FUNDUS images by applying a gray level transformation and then Contrast limited adaptive histogram equalization (CLAHE)[10]. The contrast limited adaptive histogram equalization very effective in making salient parts more visible. The image is split into disjoint regions, in each region local histogram equalization is applied and then boundaries between the regions are eliminated with a bilinear interpolation. Vessel Removal and Extrapolation [11] is used to remove complete vessel system. Illumination Equalization [12] reduce the effect caused by uneven illumination of retinal images.

Microaneurysm candidate extraction is a process that aims to spot any objects in the image showing microaneurysm like characteristics. Individual microaneurysm detectors consider different principles to extract microaneurysm candidates. In Walter et al. [13] candidate extraction is accomplished by gray scale diameter closing followed by a double thresholding. In Spencer et al. [14] the vascular map is extracted by applying 12 morphological top-hat transformations with 12 rotated linear structuring elements (with a radial resolution 15°). Then, the vascular map is subtracted from the input image, which is followed by the application of a Gaussian matched filter. The resulting image is then binarized with a fixed threshold. Since the extracted candidates are not precise representations of the actual lesions, a region growing step is also applied to that. The Circular

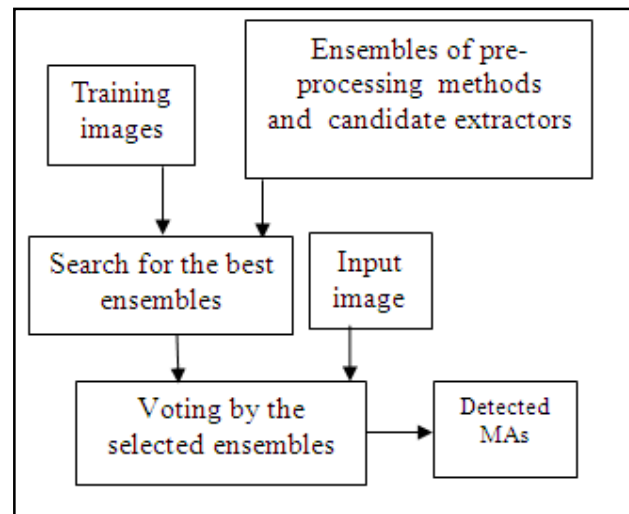


Figure 3: Flowchart of the ensemble-based framework

Hough-Transformation [15] is used for detection of small circular spots in the image using Hough-Transformation. Zhang et al. [16] method constructs a maximal correlation response image for the input retinal image to extract the candidates. Lazar et al. [17] uses pixel-wise cross-sectional profiles with multiple orientations to construct a multidirectional height map. This map assigns a set of height values that describe the distinction of the pixel from its surroundings in a particular direction to detect microaneurysms.

The flowchart of the ensemble-based framework is shown in fig 3. An ensemble E is a set of pre-processing method and candidate extractor or shortly PP, CE pairs. The meaning of a pre-processing method, candidate extractor pair is that first apply the pre-

processing method to the input image and then apply the candidate extractor to this result. That is, such a pair will extract a set of candidates HE from the original image. From HE ensemble creation is done. Ensemble creation is a process where all ensembles E from an ensemble pool E is evaluated and the best performing one $E_{best} \in E$ regarding an evaluation function on a training set is selected. This ensemble E_{best} then can be used to detect microaneurysms on unknown images. This is evaluated for both microaneurysm detection and diabetic retinopathy grading.

5. Conclusion

The double ring filter is applied on the 25 cases obtained from the ROC database. The sensitivity of the method was 68% with the 15 false positives per image. The method has several problems, could be improved further for the detection of visible microaneurysms in order to facilitate the early diagnosis of diabetic retinopathy. In the Local Rotating Cross-Section Profile Analysis method, the number of pixels to be processed is significantly reduced. An ensemble-based microaneurysm detector has high efficiency in an open online challenge with its first position. Also the grading performance of this detector in the 1200 images of the Messidor database and accuracy of 0.90+/-0.1 is achieved.

6.Reference

1. Yuji Hatanaka, Tsuyoshi Inoue, Susumu Okumura, Chisako Muramatsu and Hiroshi Fujita, "Automated microaneurysm detection method based on double-ring filter and feature analysis in retinal fundus images", 978-IEEE, 1-4673-2051-1, 2012.
2. Istvan Lazar and Andras Hajdu, "Retinal Microaneurysm Detection Through Local Rotating Cross-Section Profile Analysis", IEEE transactions on medical imaging, Vol. 32, No. 2, Feb. 2013.
3. Balint Antal and Andras Hajdu, "An Ensemble-Based System for Microaneurysm Detection and Diabetic Retinopathy Grading", IEEE transactions on biomedical engineering, Vol. 59, No. 6, Jun. 2012.
4. Y. Hatanaka, T. Nakagawa, Y. Hayashi, M. Kakogawa, A. Sawada, K. Kawase, T. Hara and H. Fujita, "Improvement of Automatic Hemorrhages Detection Methods using Brightness Correction on Fundus Images", Proc. SPIE, Vol. 6915, pp. 69153E-1-10, Feb. 2008.
5. Y. Hatanaka, T. Nakagawa, Y. Hayashi, A. Aoyama, X. Zhou, T. Hara, H. Fujita, Y. Mizukusa, A. Fujita and M. Kakogawa, "Automated detection algorithm for arteriolar narrowing on fundus images", Proc. 27th IEEE EMBS, pp. 286-290, Aug. 2005.
6. C. Muramatsu, Y. Hatanaka, T. Iwase, T. Hara and H. Fujita, "Automated selection of major arteries and veins for measurement of arteriolar-to-venular diameter ratio on retinal fundus images", Computerized Medical Imaging and Graphics, Vol. 35, No. 6, pp. 472-480, Sept. 2011.
7. L. Gagnon, M. Lalonde, M. Beaulieu, and M. C. Boucher, "Procedure to detect anatomical structures in optical fundus images," in Proc. SPIE Med. Image Process, Vol. 4322, pp. 1218-1225, 2001.
8. L. Vincent, "Morphological grayscale reconstruction in image analysis: Applications and efficient algorithms," IEEE Trans. Image process., Vol. 2, pp. 176-201, Apr. 1993.
9. T. Walter and J. Klein, "Automatic detection of microaneurysm in color fundus images of the human retina by means of the bounding box closing", Lecture Notes in Computer Science, Vol. 2526. Berlin, Germany Springer-Verlag, pp. 210-220, 2002.

10. K. Zuiderveld, "Contrast limited adaptive histogram equalization", *Graphics Gems*, Vol. 4, pp. 474–485, 1994.
11. S. Ravishankar, A. Jain and A. Mittal, "Automated feature extraction for early detection of diabetic retinopathy in fundus images", in *Proc. IEEE Conf. Comput. Vision Pattern Recog.*, pp. 210–217, 2009.
12. A. A. A. Youssif, A. Z. Ghalwash and A. S. Ghoneim, "Comparative study of contrast enhancement and illumination equalization methods for retinal vasculature segmentation", in *Proc. Cairo Int. Biomed. Eng. Conf.*, pp. 21–24, 2006.
13. T. Walter, P. Massin, A. Arginay, R. Ordonez, C. Jeulin, and J. C. Klein, "Automatic detection of microaneurysms in color fundus images," *Med. Image Anal.*, Vol. 11, pp. 555–566, 2007.
14. T. Spencer, J. A. Olson, K. C. McHardy, P. F. Sharp and J. V. Forrester, "An image-processing strategy for the segmentation and quantification of microaneurysms in fluorescein angiograms of the ocular fundus", *Comput. Biomed. Res.*, Vol. 29, pp. 284–302, 1996.
15. S. Abdelazeem, "Microaneurysm detection using vessels removal and circular hough transform," in *Proc. 19th National Radio Sci. Conf.*, pp. 421–426, 2002.
16. B. Zhang, X. Wu, J. You, Q. Li, and F. Karray, "Detection of microaneurysms using multi-scale correlation coefficients", *Pattern Recogn.*, Vol. 43, No. 6, pp. 2237–2248, 2010.
17. I. Lazar and A. Hajdu, "Microaneurysm detection in retinal images using a rotating cross-section based model," in *Proc. IEEE Int. Symp. Biomed. Imag.*, pp. 1405–1409, 2011.