



ISSN 2278 – 0211 (Online)

Pathological Fracture of Femur Due to Hydatid Cyst- A Case Report

Dr. Kurukunda Venkateswarlu

M.S. (Orthopedics), Associate Professor, Department of Orthopedics,
Kurnool Medical College, Kurnool, Andhra Pradesh, India

Dr. Avula Renuka Devi

M.D. (Microbiology), Associate Professor, Department of Microbiology,
Kurnool Medical College, Kurnool, Andhra Pradesh, India

Dr. Madiga Nagaraju

M.S. (Orthopedics), Assistant Professor of Orthopedics,
Kurnool Medical College, Kurnool, Andhra Pradesh, India

Abstract:

Introduction: Hydatid disease caused by Echinococcus parasite commonly presents as a cystic disease in, Liver, Lung, Spleen and Brain. Hydatid cyst in the bone is a rare manifestation, our study presents cystic disease in entire femur with multiple fractures in femur, which is a rare presentation.

Case report: A female patient aged 58 years presented with pain and swelling left thigh gradually increasing in nature since 1 year. The patient couldn't walk since 2 weeks. Clinically there is a huge swelling of left thigh with a crepitus. No other complaints from any other part of the body.

Conclusion: Hydatid disease of the bone poses difficulties in the treatment, because bone biopsy cannot be attempted to avoid the danger of anaphylaxis reactions. We did closed Intramedullary Supracondylar nailing of the femur, which took 12 months for healing with shortening of the limb.

Keywords: Hydatid cyst, Pathological fracture, Nailing, Supracondylar

1. Introduction

Hydatid cystic disease in human beings is caused by a parasite Echinococcus granulosus. It is very common in India. The disease starts without symptoms for a very long time. The disease is caused by accidental contamination of eggs by water or food because of fondling and handling of pet animals. Sheep and cattle act as intermediate hosts. Dogs are definitive hosts. Human beings act as an accidental intermediate host. Liver is the commonest organ (60%) for hydatid cyst followed by Lung, Liver and Spleen. Skeletal hydatid disease is very rare accounting for 1 to 2%. Spine is a common bone to be affected. Femur is a very rare site to be affected [1][2].

Primary bone hydatid cyst develops when the scoleces are localized in the bone. These cysts may remain in the bone without symptoms for years. Thickness of the bone cortex will limit the extra-osseous expansion of the cyst. [6].

The patients may feel slight pain initially. Here we have a case of hydatid cyst which caused pathological fracture of femur causing extra-osseous spread of cyst.

2. Case Report

A 58 year old female who is an agriculturalist by occupation presented at our hospital with pain and swelling of left thigh. Patient was not able to bear weight on left leg and patient was not able to walk since 2 weeks. The patient had a CT guided biopsy 8 months back at another hospital, as they suspected some bone cyst of the femur. The report came as a Hydatid cyst of the femur.

Laboratory examination revealed mild Anaemia (Hb : 8g/100ml), ESR : 24mm/hr. Normal leukocyte count. Eosinophils are 6%.

X-ray revealed multiple cystic areas of left femur with pathological fracture of femur at lower third. It also has shown non union of fracture neck of femur which the patient has revealed that she sustained it when she was 20 yrs of age. Ultrasound of abdomen did not reveal any abnormality, CT scan of brain was normal. Magnetic Resonance imaging of left thigh revealed a lesion filling the whole medullary cavity from trochanter to condyles of femur, its extension into soft tissues was also found.

The patient was well informed about the prognosis of the disease, and was planned for excision biopsy and internal fixation of the fracture. The patient was given 2 packets of compatible blood. Fracture was approached by lateral approach of femur. The cystic capsules extending into soft tissues from the bone were carefully excised. Thorough curettage of the bone using solid intramedullary reamers of the femur was done. All the operative site was irrigated with normal saline and Betadine solution. The fracture was fixed

by an Intramedullary Supracondylar nail by patellar tendon split approach. The patient was given 3 cycles of Albendazole tablets with a dosage of 400mg twice in a day for 30 days. Biopsy report came as laminated membrane consistent of hydatid cyst.

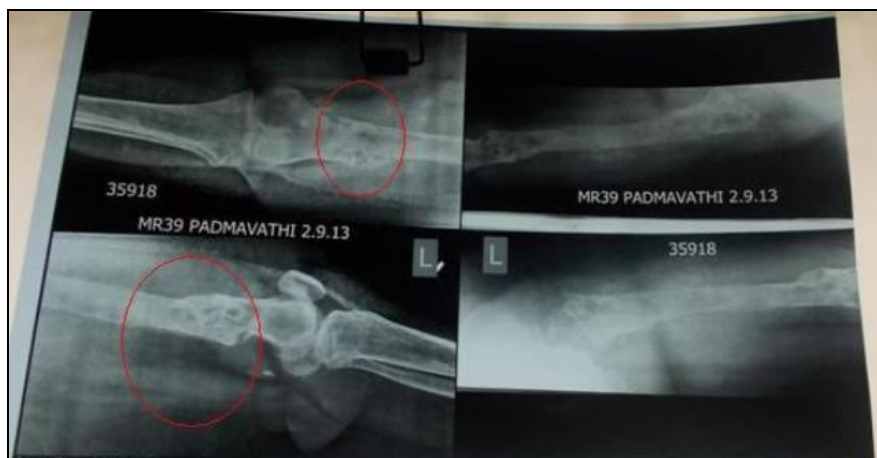

Figure 1: Preoperative X-ray of femur with pathological fracture of femur

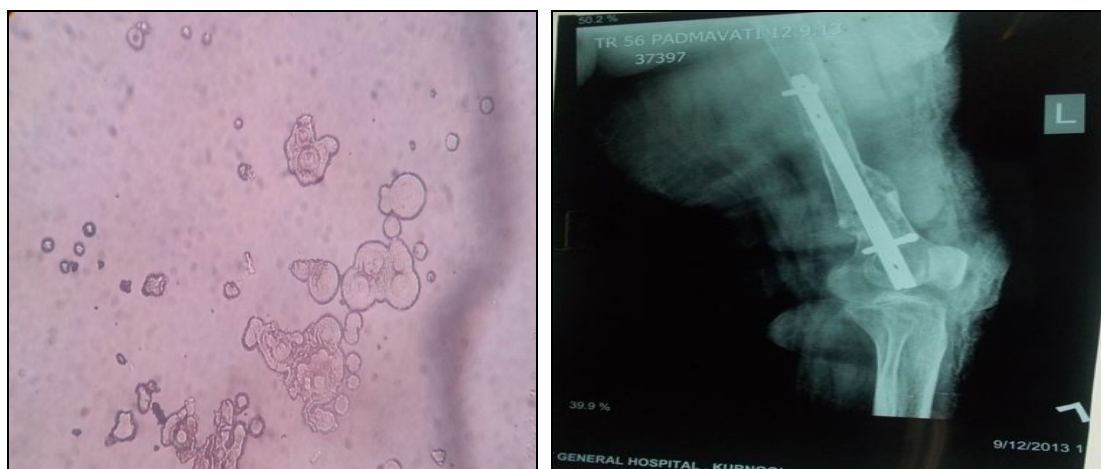


Figure 2: P.O. x-ray, Microscopic slide of scoleces

Microbiological analysis of fluid revealed scoleces. The patient was followed every monthly intervals. The patient started walking with a walker frame after 6 months. The patient came on 20-12-2014, Xray revealed fracture united well.

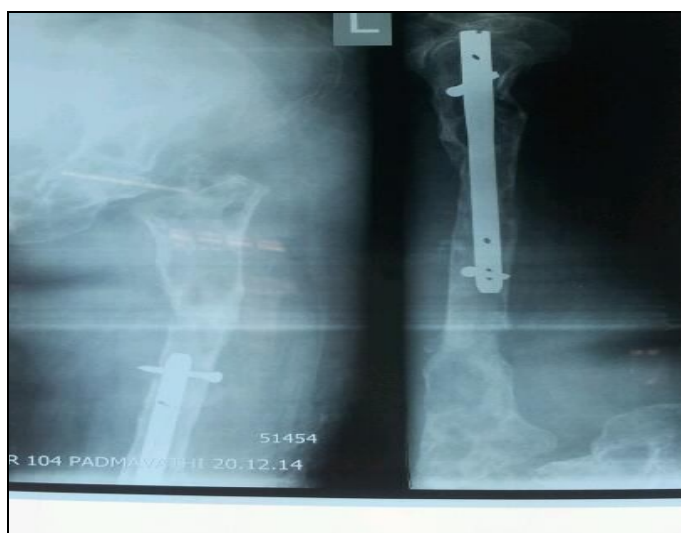

Figure 3: Post-operative X ray on 20-12-2014

3. Discussion

Hydatid cystic disease caused by *Echinococcus granulosus* is very common in India. It affects most of the vital organs in the body with Liver is being affected most. Skeletal manifestations are rare affecting vertebrae mostly followed by long bones like femur, tibia etc. The disease in the bones and the joint begins once the blood borne scolex settles there. But most of the patients will be unaware of the disease remaining asymptomatic for many years. It is a very slow process so it is never presented during the childhood, even if the child has this parasitic infection. Hydatid cyst like any other cysts begins at the metaphysis spreading slowly all along the diaphysis, giving rise to a multilocular cystic appearance scalloping the cortex of the bone, and joint surface is never breached.

The cyst growth in the bone is different when compared to soft tissue involvement like Liver; the cyst in the bone is unable to expand and fragments causing diffuse spreading of daughter cysts resulting in polycystic nature.

The diagnosis of bone hydatid is difficult as it is often confused by tumours of the bone and Fibrous dysplasia. Immunological tests and Casoni test are often negative; hence preoperative diagnosis is very difficult in diagnosing bone hydatid disease [3]. Despite the reports of spillage of cystic fluid leading to anaphylactic shock, fine needle aspiration under Ultrasound or CT guide is safe for diagnosis and for treatment of hydatid disease.

If you excise the cyst carefully it gives a good prognosis. Yeldiz and his team has reported 10 cases of bone hydatid disease treated with curettage and treatment with Betadine solution and filling the defect with bone cement[8]. Recurrence rate in bone hydatid is 30%. Most authors consider that hydatid cyst of bone should be considered as locally malignant and treatment should be wide excision. Per-operatively the cyst should be thoroughly curetted and washed with hypertonic saline, povidone iodine solution, silver nitrate (0.5%), the dead space can be filled with either bone graft or bone cement. The fractures can be treated by stabilization with nailing. Albendazole is the most effective drug in the treatment of Hydatid cyst continued for 4 weeks with a 400mg twice a day dosage. The treatment should be continued for 3 months.

Aim of our study is to increase the awareness of the skeletal hydatid disease, as the laboratory diagnostic tools are not very specific.

4. Conclusion

Pathological fracture with a hydatid cyst is a challenging condition to manage, as the disease manifests lately eroding the entire cortex of the bone by multiple cysts. We have to excise the tumour thoroughly and treat it chemically with hypertonic saline and Betadine solution. Our plan here to treat the fracture of lower third of femur with Intramedullary supracondylar nail has given good result, although union of the bone has taken long time. We have taken appropriate precautions by starting on higher antibiotics postoperatively as the secondary infection is very common in this disease, this may complicate our treatment. Fortunately, our management was uneventful.

5. References

1. A. Herrera and A. A. Martinez, "Extraspinale bone hydatidosis," *Journal of Bone and Joint Surgery A*, vol. 85, no. 9, pp. 1790–1794, 2003.
2. M. Tüzün and B. Hekimoflu, "Various locations of cystic and alveolar hydatid disease," *Journal of Computer Assisted Tomography*, vol. 25, no. 1, pp. 81–87, 2001.
3. W. Zhang, J. Li, and D. P. McManus, "Concepts in immunology and diagnosis of hydatid disease," *Clinical Microbiology Reviews*, vol. 16, no. 1, pp. 18–36, 2003.
4. G. S. Sapkas, D. P. Stathakopoulos, G. C. Babis, and J. K. Tsarouchas, "Hydatid disease of bones and joints: 8 cases followed for 4–16 years," *Acta Orthopaedica Scandinavica*, vol. 69, no. 1, pp. 89–94, 1998.
5. A. Papanikolaou, "Osseous hydatid disease," *Transactions of the Royal Society of Tropical Medicine and Hygiene*, vol. 102, no. 3, pp. 233–238, 2008.
6. Y. Tomak, N. Dabak, B. Gulman, T. N. Karaismailoglu, T. Basoglu, and L. Incesu, "Hydatid disease of the left femur: a case report," *Bulletin Hospital for Joint Diseases*, vol. 60, no. 2, pp. 89–93, 2001.
7. M. K. Booz, "The management of hydatid disease of bone and joint." *Journal of Bone and Joint Surgery B*, vol. 54, no. 4, pp. 698–709, 1972.
8. Y. Yildiz, K. Bayrakci, M. Altay, and Y. Saglik, "The use of polymethylmethacrylate in the management of hydatid disease of bone," *Journal of Bone and Joint Surgery B*, vol. 83, no. 7, pp. 1005–1008, 2001.