



ISSN 2278 – 0211 (Online)

Outcome of Management of Nasal Trauma in Port-Harcourt, Nigeria

Dr. Nwogbo AC

Consultant, Department of Ear, Nose & Throat,
University of Port-Harcourt Teaching Hospital, Port-Harcourt, Nigeria

Dr. Uyanwanne S N

Consultant, Department of Ear, Nose & Throat,
University of Port-Harcourt Teaching Hospital, Port-Harcourt, Nigeria

Dr. Mbalaso OC

Consultant, Department of Ear, Nose & Throat, University of Port-Harcourt Teaching Hospital, Port-Harcourt, Nigeria

Abstract:

Introduction: Nasal bone is the most frequently fractured facial bone because of its prominence and delicate structure. The etiology of nasal trauma can vary in different places. Port-Harcourt is one of the Niger Delta states and a major city in South-South Nigeria with a rising trend in communal and social conflicts resulting in injuries. This study aimed to determine the etiological factors and outcome of management of nasal trauma among patients in University of Port-Harcourt Teaching Hospital.

Materials and Methods: This was a retrospective study of patients that presented to the Ear, Nose and Throat (ENT) department, of UPTH, Port-Harcourt, Nigeria with nasal trauma within a period of 6 years (from June 2012 to July 2018). Data was retrieved from medical records, analyzed using descriptive statistics and results presented in tables.

Results and Discussion: A total of sixty-six (66) patients with nasal trauma were seen within the study period. There were 48 males and 18 females. The age range was 2 years to 72 years with the majority of patients in the age range 21-30 years (42.4%). Assaults constituted the highest etiological factor (45.5%) followed by road traffic accident (24.2%). The commonest symptom was epistaxis (90.9%). About 60% of patients received conservative treatment while 30.3% had surgical intervention. A significant improvement in nasal deformity, aesthetic and airway was achieved in all the patients that had surgical intervention.

Conclusion: Assault as the commonest etiological factor implicated in nasal trauma may be due to increase in social unrest in Niger-Delta. Close reduction can significantly improve structural and functional complications of simple non-comminuted nasal fracture.

Keywords: Nasal fracture, Close reduction and Port-Harcourt

1. Introduction

Nasal trauma is a common presentation in our environment. Nasal bone is the most frequently fractured facial bone because of its prominence and delicate structure¹. Nasal fractures rank third in the incidence of all human fractures behind clavicle and the wrist².

The etiology of nasal trauma can vary in different places. In children, the mechanisms of injury vary by age³. Road traffic accident has been reported as the commonest cause of nasal trauma accounting for 57.5% in Ilorin, North-Central Nigeria⁴. However, assaults was the most implicated cause of facial trauma in developed countries⁵. Other causes could be fight, sports injury, fall, industrial accidents and so on.

In acute nasal trauma, the presentations are epistaxis, nasal pains, nasal deformity, facial bruises, nasal obstruction, and periorbital swelling. This may depend on the type of the nasal fracture and co-existing midfacial injuries. Epistaxis was reported to be the commonest presentation of nasal trauma⁴. Males are affected approximately twice than female in both children and adults with a peak incidence occurring at second to third decades of life¹. According to modified Murray classification, nasal fracture is classified based on clinical findings as in fig1⁶. Closed reduction is suitable for simple non-comminuted nasal fractures (type I-III) while comminuted fracture with severe loss of nasal support and septal injuries would require an open technique⁷. Open reduction is also necessary for patients not satisfactorily managed by closed reduction⁷. Closed reduction requires the repositioning of the nasal bone in three dimensions: elevation of depressed bones, depression of elevated bones and restoration of symmetry of the nasal pyramid and its midline alignment⁸. It involves the use of freer elevator, Walsham's and Ashe's forceps. In the management of displaced nasal

fracture, the timing of reduction is very vital. Early intervention has been found to raise the patient satisfactory rate⁹. Reduction of nasal fracture is done either before the appearance of significant edema or after 3-5 days to allow edema to resolve^{10, 11}. It is difficult to reduce a nasal fracture after 2 weeks because it has healed by this time¹¹. Delay in management can result in complications such as airway obstruction, cosmetic deformity, septal perforation and so no. Nasal injuries in children may lead to devastating growth retardation of the nose and midface¹.

Figure 1-Modified Murray classification of nasal fracture⁶

- Type I: Injury restricted to soft tissue
- Type IIa: Simple, unilateral undisplaced fracture
- Type IIb: Simple, bilateral undisplaced fracture
- Type III: Simple displaced fracture
- Type IV: Closed comminuted fracture
- Type V: Open comminuted fracture or complicated fracture

Port-Harcourt is one of the Niger Delta states and a major city in South-South Nigeria with a rising trend in communal and social conflicts resulting in body injuries. There is need to determine the etiological factors and outcome of management of nasal trauma among patients in University of Port-Harcourt Teaching Hospital.

2. Materials and Methods

This was a retrospective study of patients that presented to the Ear, Nose and Throat (ENT) surgery of the UPTH, Port-Harcourt, Nigeria with nasal trauma within a period of 6years (from June 2012 to July 2018). Data retrieved from medical records include demographic variables of age and gender, etiological factors, symptoms, treatment offered and outcomes. The data were analyzed using descriptive statistics and results presented in tables.

3. Results

A total of sixty-six (66) patients with nasal trauma were seen within the study period. There were 48 males and 18 females with a M:F ratio of 2.7:1. The age range was 2 years to 72 years with the majority of patients in the age range 21-30 years (42.4%) [table 1]. Assaults constituted the highest etiological factor for nasal trauma (45.5%). Others were road traffic accident (24.2%), falls (19.7%), sports injury (7.6%) and industrial accident (3.0%) [table2]. The commonest symptom was epistaxis (90.9%) followed by nasal blockage (68.1%) and nasal deformity (45.5%) [table 3]. About 60% of patients received conservative treatment which had either undisplaced nasal fracture or soft tissue injury while 39.4% had surgical interventions. Conservative treatment involved anterior nasal packing, parenteral antibiotics and analgesics. The surgical interventions were closed reduction of nasal/septal fracture and incision and drainage of septal hematoma. A significant improvement in nasal deformity, aesthetic and airway was achieved in all the patients.

Age Range	N (%)
0-10	7 (10.6)
11-20	9 (13.6)
21-30	28 (42.4)
31-40	10 (15.1)
41-50	6 (9.1)
51-60	3 (4.5)
61-70	2 (3.0)
71-80	1(1.5)
Total	66 (100)

Table 1: Age Range of Patients with Nasal Trauma

Etiological factors	N (%)
Assaults	30 (45.5)
RTA	16 (24.2)
Fall	13 (19.7)
Sports injury	5 (7.6)
Industrial accident	2 (3.0)
Total	66 (100)

Table 2: Etiological Factors Implicated in Nasal Trauma

Symptoms	Number	Percentage (%)
Epistaxis	60	90.9
Nasal obstruction	45	68.2
Nasal bruises	20	30.3
Nasal deformity	30	45.5
Nasal pains	25	37.9
Loss of smell	12	18.2

Table 3: Patient's Symptoms at Presentation

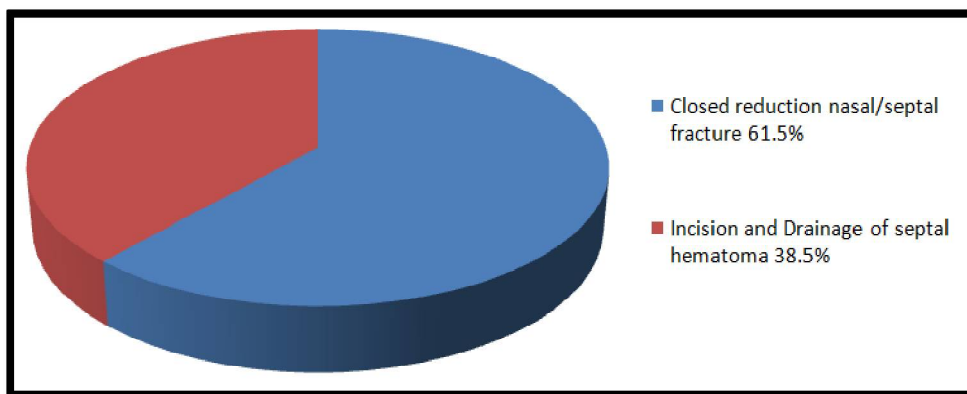


Figure 1: Various Surgical Interventions

4. Discussion

There was a marked male preponderance among patients with nasal trauma in our study. This is similar to other studies^{4, 5, 12}. This may be because males are more in the workforce and take higher risks. Age range 21-30 years had the highest number of cases which is in agreement with similar study in Ilorin, North-Central Nigeria⁴. Also, this is in support with the findings of Laski *et al* in New Jersey⁵. It could be because this age group is made up of young adults who are more adventurous. Adeyemo *et al* reported that this age group take part in dangerous exercises, drive carelessly and are more likely to be involved in violence¹³. Contrarily, Nwosu and Nnadede in Enugu reported peak incidence of septal hematoma to be between 10-18 years age group and trauma was implicated in most of the cases¹⁴.

Assault (45.5%) was the commonest etiological factor implicated in nasal trauma in this study. This is in agreement with the findings of other studies^{5, 15}. This fact may be attributed to increase in social vices in Niger-Delta and developed countries. However, road traffic accident remained the major etiological factor of maxillofacial trauma in all regions except in North-Eastern region where assaults was the major cause¹³. Afolabi and Alabi 2010 in Ilorin, Nigeria reported road traffic accident as the commonest cause of nasal trauma followed by assaults⁴ and other works found automobile accident and sports injury as the most frequent factors^{16, 17}. Also, Udeabor *et al* 2014 in Port-Harcourt, Nigeria found road traffic accident followed by assaults as the commonest cause of maxillofacial fractures¹⁸. Fall has been reported as the commonest cause in another work in Germany¹⁹. This is different in pediatric population where sports injury was predominant³.

Epistaxis (90.9%) was the commonest symptom in our series. Similar findings were noted in these studies^{4, 12}. In Ile-ife, Nigeria epistaxis was reported as the commonest presentation of maxillofacial trauma^{20, 21}.

In this study, 39.4% of cases had surgical interventions, closed reduction of nasal/septal fracture (61.5%) and incision and drainage of septal hematoma (38.5%). All the patients had significant improvement in nasal deformity, aesthetic and airway. Similarly, Hung *et al* in China found a significant improvement in nasal aesthetic and airway in patients with nasal fracture who had a closed reduction⁸ and Bremke *et al* in Germany reported that closed reposition of nasal bone is the therapy of choice in uncomplicated nasal bone fractures¹⁹. Also, Han-Kyul *et al* in Korea, reported that closed reduction is generally an effective treatment for nasal bone fracture but in severe concurrent septal or comminuted fracture with depression open reduction should be considered²². Contrarily, another study in Korea showed that more active treatment such as open reduction or septoplasty and rhinoplasty may lead to better results than closed reduction²³ and DeFatta *et al* in Texas found a statistically significant reduction in the number of patients requiring a revision rhinoplasty for residual deformity following an open reduction as compared with closed reduction in management of acute nasoseptal fracture²⁴.

Incision and drainage of septal hematoma accounted for 38.5% of surgical intervention following nasal trauma in this study. Nwosu and Nnadede in Enugu reported 65.2% of patients with septal hematoma from nasal trauma who benefitted from incision and drainage¹⁴. Bremke *et al* in Germany found 5% of septal hematoma¹⁹. The differences may be attributed to the sample size and septal hematoma may be more common than acknowledged.

Conclusion: Assault as the commonest etiological factor implicated in nasal trauma may be due to the increase in social unrest in Niger-Delta. Close reduction can significantly improve structural and functional complications of simple non-comminuted nasal fracture.

5. References

- i. Cummings CW, Flint PW, Haughey BH, Richardson MA, Robbins KT, Schuller DE, et al. (2005). Nasal fracture. In: Cummings otolaryngology head and neck surgery. USA: Mosby, inc. 4(4):4135-4139.
- ii. Byron J. B Jonas TJ, Newlands S. D. (2006). Nasal fractures. In: Head and Neck Surgery- Otolaryngology. 2(1):1221-1235.
- iii. Liu C, Legocki AT, Mader NS, Scott AR. (2015). Nasal fractures in children and adolescents: Mechanisms of injury and efficacy of closed reduction. Int J Pediatr Otorhinolaryngol, 79:2238-2242.
- iv. Afolabi O, Alabi B. (2010). Aetiological profile of nasal trauma in Ilorin north-central Nigeria. Niger J Med, 19:348-351.
- v. Laski R, Ziccardi VB, Broder HL, Janal M. (2004). Facial trauma: A recurrent disease? The potential role of disease prevention. J oral Maxillofac Surg, 62:685-688.

- vi. Higuera S, Lee EI, Cole P, Hollier Jr LH, Stal S.(2007). Nasal trauma and the deviated nose. *Plast Reconstr Surg*, 120:64S-75S.
- vii. Koca Ç, Kizilay A.(2015). Management of nasal fractures. *J Emerg Med Trauma Surg Care*, 2:120-127.
- viii. 8Hung T, Chang W, Vlantis AC, Tong MC, Van Hasselt CA. (2007). Patient satisfaction after closed reduction of nasal fractures. *Arch facial plast Surg*, 9:40-43.
- ix. Yilmaz MS, Guven M, Varli AF. (2013) Nasal fractures: Is closed reduction satisfying? *J Craniofac Surg*, 24:236-238.
- x. Chan J, Most SP. Diagnosis and management of nasal fractures.(2008). *Operative Techniques in Otolaryngology-Head and Neck Surgery*, 19:263-266.
- xi. PL Dhingra (ed). (2009). Trauma to the face. In: *Disease of the ear, nose and throat*, 4th edn. India: Elsevier; p172.
- xii. Daniel M, Raghavan U. (2005). Relation between epistaxis, external nasal deformity, and septal deviation following nasal trauma. *Emerg Med J*, 22:778-779.
- xiii. Adeyemo WL, Ladeinde AL, Ogunlewe MO, James O. (2005). Trends and characteristics of oral and maxillofacial injuries in nigeria: A review of the literature. *Head & Face Med*, 1:726-735.
- xiv. Nwosu JN, Nnadede PC. (2015). Nasalseptal hematoma/abscess: Management and outcome in a tertiary hospital of a developing country. *Patient Prefer adherence*. 9:1017.
- xv. Çil Y, Kahraman E. (2013). An analysis of 45 patients with pure nasal fractures. *Turk J Trauma and Emerg Surg*, 19:152-156.
- xvi. Basheeth N, Donnelly M, Munish S. (2015) Acute nasal fracture management: A prospective study and literature review. *The Laryngoscope*, 125:2677-2684.
- xvii. Vilela F, Granjeiro R, Júnior CM, Andrade P.(2014). Applicability and effectiveness of closed reduction of nasal fractures under local anesthesia. *Int Aich Otorhinolaryngol*, 18:266-271.
- xviii. Udeabor S, Akinbami B, Yarhere K, Obiechina A. (2014). Maxillofacial fractures: etiology, pattern of presentation, and treatment in University of Port Harcourt teaching hospital, Port Harcourt, Nigeria. *J Dent Surg*, 200-209.
- xix. Bremke M, Gedeon H, Windfuhr J, Werner J, Sesterhenn A. (2009). Nasal bone fracture: Etiology, diagnostics, treatment and complications, *Laryngo-rhino-otologie*.88:711-716.
- xx. Eziyi J, Akinpelu O, Amusa Y, Eziyi A (2009). Epistaxis in Nigerians: A 3-year experience. *East and Central Afri J Surg*, 14:93-98.
- xxi. Akinpelu O, Amusa Y, Eziyi J, Nwawolo C. (2009). A retrospective analysis of aetiology and management of epistaxis in a south-western nigerian teaching hospital. *West Afri J med*, 28-35.
- xxii. Park H-K, Lee J-Y, Song J-M, Kim T-S, Shin S-H. (2014). The retrospective study of closed reduction of nasal bone fracture. *Maxillofac Plast Reconstr Surg*, 36:266-272.
- xxiii. Park CH. (2011). The current knowledge of the treatment of nasal bone fractures. *J. Rhinol*, 18:94-101.
- xxiv. DeFatta RJ, Ducic Y, Adelson RT, Sabatini PR. (2008). Comparison of closed reduction alone versus primary open repair of acute nasoseptal fractures. *J. Otolaryngol Head and Neck Surg*, 37:502-510.