

THE INTERNATIONAL JOURNAL OF SCIENCE & TECHNOLEDGE

Comparative Study between Magnetic Resonance Imaging and Computed Tomography Scan Imaging in Long Bone Primary Osteosarcoma Diagnosis in Riyadh Hospital, Saudi Arabia

Dr. Halima Hawesa

Assistant Professor, Department of Radiology,
Princess Nourah Bint Abdulrahman University, Saudi Arabia

Sara Alsaleh

Student, Department of Radiology,
Princess Nourah Bint Abdulrahman University, Saudi Arabia

Aseel Alibrahim

Student, Department of Radiology,
Princess Nourah Bint Abdulrahman University, Saudi Arabia

Wadha alkhaldi

Student, Department of Radiology,
Princess Nourah Bint Abdulrahman University, Saudi Arabia

Modi Alotaibi

Student, Department of Radiology,
Princess Nourah Bint Abdulrahman University, Saudi Arabia

Lujain Alshreef

Student, Department of Radiology,
Princess Nourah Bint Abdulrahman University, Saudi Arabia

Abstract:

Aims and Objective: The aim of this project is to identify the most common radiology imaging protocol to diagnosis Long Bone Primary Osteosarcoma (LBPO) in Riyadh hospitals.

Method: This is a retrospective study covered data files of five LBPS patients from Security Forces Hospital in Riyadh. These reported cases were going through radiographs x-ray, CT and MRI imaging protocols. The CT and MRI protocols are compared based on finding and final diagnosis.

Results: Patient's age average is 16 years old. Two cases (40%) were performed CT with MRI, while three cases (60%) were perform MRI directly with no CT imaging.

Conclusion: The final diagnosis of all patients with (LBPO) is based on special MRI imaging protocols.

Keywords: Osteo sarcoma (OS), long bone primary Osteosarcoma, tumor Imaging

1. Introduction

Bones help support and protect our vital organs, such as the skull bones, breast bone (sternum), and ribs. These types of bones are often referred to as flat bones. Other bones, like in in the arms and legs, make a framework for our muscles that helps us to move. These are called long bones (1).

New blood cells are made in the bones, it is done in the soft inner part of some bones and called the bone marrow, which contains blood-forming cells. New red blood cells, white blood cells, and platelets are made in bone marrow. Bones provide the body with a place to store minerals such as calcium (1).

Bones are very hard, and no change in the shape once reaching adulthood. Like all other tissues of the body, bones have many kinds of living cells. Two main types of cells in our bones help them stay strong and keep their shape. These cells are Osteoblasts and Osteoclasts. Osteoblasts help build up bones by forming the bone matrix (the connective tissue and minerals that give bone its strength). Osteoclasts break down bone matrix to prevent excessive building up, and help bones keep their proper shape. These cells help control the amount of these minerals in the blood (1).

Osteosarcoma is malignant tumor that develops in bone. Like the osteoblasts in normal bone, the cells that form this cancer make bone matrix. But the bone matrix of an osteosarcoma is not as strong as that of normal bones. Most osteosarcomas occur in children and young adults between the ages of 10 and 30, but osteosarcoma can occur at any age (2). Most tumors develop in the bones around the knee, either in the distal femur or the proximal tibia. The proximal

humerus is the next most common site. However, osteosarcoma can develop in any bone, including the bones of the pelvis, shoulder, and jaw, this is especially true in older adults (3). Osteosarcomas can be either primary or secondary, and these have differing demographics. Primary osteosarcoma: typically occurs in young patients (10-20 years) 75% occurring before the age of 20 because the growth centers of the bone are more active during puberty/adolescence with slight male predominance. Secondary osteosarcoma: occurs in the elderly; usually secondary to malignant degeneration of Paget disease, extensive bone infarcts and post-radiotherapy (4). A metastatic osteosarcoma has clearly spread to other parts of the body. Most often it spreads to the lungs, but it can also spread to other bones, the brain, or other organs about 1 out of 5 osteosarcoma patients has metastatic spread at the time of diagnosis. These patients are harder to treat (5).

Osteosarcoma diagnosed first by plain radiograph shows diffuse calcification, then MRI which shows distribution of the tumor within the bone and the extent of any associated soft tissue mass and CT scan is used in the staging of pulmonary metastases (6). Magnetic resonance imaging of osteosarcoma is the most important imaging technique for the accurate local staging of osteosarcoma; in addition, it assists in determining the most appropriate surgical management. For the purposes of staging, assessment of the relationship of a tumor to the anatomic compartment in which it originated and to other adjacent compartments is of vital importance. Compartments include individual bones, joints, and clearly defined, fascially enclosed soft tissue spaces. Disease confined to its original compartment is associated with a better prognosis than is disease that has spread into other compartments (7).

The most usable sequence for determining the longitudinal extent of disease is the T1-weighted spin-echo sequence. The use of short-tau inversion recovery (STIR), seen in the images below, may significantly lead to an overestimation of disease, because edema and marrow hyperplasia may show high signal intensity similar to that of tumor. The maximum longitudinal extent of the tumor should be measured, and its maximal distance from the articular surface of the nearest joint should be recorded. The longitudinal extent is usually maximal within medullary bone, but occasionally, intracortical extension is more extensive. The most planes used are sagittal coronal and sometimes all three planes used (sagittal, coronal and axial) (8). STIR sequences are slightly more sensitive; T1 sequences are slightly more specific (9). CT scans are used to see if the tumor has grown into nearby muscle, fat, or tendons. A CT scan of the chest is used to look for spread of the cancer to the lungs and to see the spread of the cancer to other parts of the body. CT is used to image conventional osteosarcoma, need do detection of small amounts of mineralized osseous matrix that are undetectable on radiographs. The modality is infrequently required in local evaluation of tumors in the long tubular bones, but it is the most accurate modality for staging pulmonary metastases. CT is useful for detecting small amounts of calcification, although ultrasonography may be helpful in evaluating soft tissue extension when such extension is superficial (10,11). According to Oncology register of King Faisal Specialized Research Center there is a tendency to increase long bone primary osteosarcoma among Saudi society, 6.8% of these osteosarcomas are children less than 15 years old. These types of sarcoma came in fourth place than the other leukemia, lymphoma, brain tumors and nervous system (12). Since LBPO is mainly tumor affect young people, and youth are the dominant in Saudi society, Therefore, the primary aim of the current project is to assess the diagnose modality of Long Bone Primary Osteosarcoma, and compare the MRI and CT Imaging procedure effectiveness in diagnosis. This study is conducted based of the data obtained from Security Forces Hospital to detect imaging modalities used in osteosarcoma cases.

2. Methods and Materials

This retrospective study is approved by scientific research committee at Princess Nourah bint Abdulrahman University. The records of five patients with long bone primary osteosarcoma were viewed. This data was collected from Security Force Hospital in Riyadh, Saudi Arabia. Only record of patient age 20 years or less are included. The recorded data are personal information, and method of diagnostic as shown in Table (1). Medical charts, and radiological images for CT, MRI and Plain X-RAY also provided by the hospital records. The data was analyzed using Excel statistical package. only descriptive data analysis was performed due to insufficient data to carry other advance statistical tests.

Case	Diagnostic Method	Technical
1	MRI	Axial t1 Axial t1 fat sat Axial t2 fat sat Axial, sagittal and coronal T1 fat sat after iv contrast
2	MRI	Multipanar, multisequential MRI of the wrist before and after I.V Gadolinium injection.
3	1- CT	1- CT chest routine 2- Multipanar Mutisequential MRI of leg contrast enhancement
4	2- MRI	Multisequential and multipanar MRI of the right thigh was performed
5	MRI	1- CT routine forearm 2- MRI of the left forearm Coronal and axial T2. Coronal, axial and sagittal STIR with axial T1 fat sat Followed by axial and coronal T1 after I.V Gadolinium

Table 1: Imaging Protocols (MRI, CT)

3. Results and Data Analysis

The results of this study showed that the incidence of osteosarcoma is mainly among young people aged 10 to 20 with average 16 years old. MRI imaging protocols, stated in Table 1, are used in all reviewed cases, with two cases did CT imaging prior MRI imaging procedures.

Case	Age	Gender	Anatomical Site	Diagnostic Method	Findings
1	11	M	R-fibula	MRI	Moderate size osteolytic, exophytic mass involving the proximal metadiaphysis of the proximal right fibula with prominent heterogenous soft tissue swelling
2	19	F	L-distal Ulna	MRI	There is destructive mass lesion occupying the distal shaft metadiaphysis of the left ulna bone, it is extending to the distal epiphysis with small are preserved related to the ulnar styloid process
3	12	F	Leg	1-CT 2-MRI	1- There are multiple small and tiny subcentimetric scattered pulmonary nodules seen across both lung field more at the right lower lobe suggestive of pulmonary metastasis 2- There is proximal meta-diaphysial involvement of the aggressive mass. On T1. it shows intermediate sig of ossified components, and peritumoral edema. It shows predominantly high signal intensity on T2 F mild intra-articular extension
4	18	F	R-thigh	MRI	There is heterogeneous enhancing mass lesion involving the right distal femur metaepiphysis
5	20	M	L-forearm	1-CT 2-MRI	1- Asked to do MRI 2- There is a huge mainly intramedullary destructive mass lesion with large son tissue component seen involving the left humeral metaphysis

Table 2: Sample Consists of 5 Patients. 3 Patients with Diagnostic Method MRI, 2 Patients with CT Scan

Patient personal information, method of diagnosis and finding for each case are showed in Table (2). Figure (1) shows the percentage of imaging methods in the studied case.

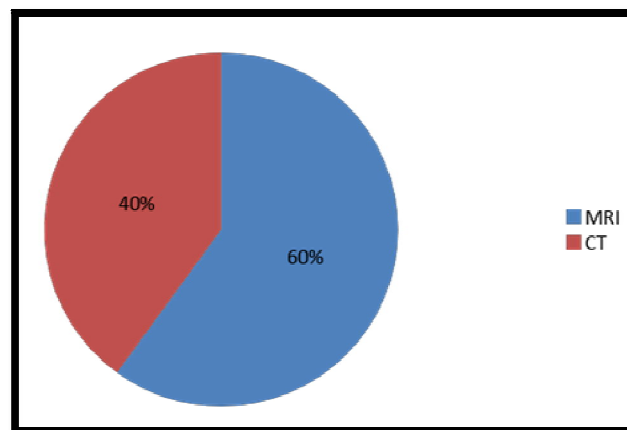


Figure 1: The Percentage of MRI and CT in the Reviewed Cases

4. Discussion

The disease of primary long bone osteosarcoma is increasing among young Saudis as reported by local Saudi magazines, and Saudi carcinoma society (12). The main imaging method for OS are CT and MRI. However, MRI is the final method for diagnosis for most OS cases.

Although most studies in literature supported the idea that MRI is good tool to detect osteosarcoma injuries, they all stated that Osteosarcoma plain radiograph shows diffuse calcification, and MRI shows distribution of the tumor within the bone and the extent of any associated soft tissue mass. Whereas CT scan is used in the staging of pulmonary metastases (6).

In this study five records of Primary long bone osteosarcoma patient are viewed, and information of these medical records are presented in Table 1- 2, and figure 1. The data included in Figure 1 showed that MRI protocols are more common than CT procedure for diagnosis OS cases, and this is in agreement with pervious published result (8-10).

The reviewed cases in this study found that the number of female patients is more than the male patient, which disagree with Saudi published statistical (12) that stated males are more effected by OS than females. This disagreement is not surprising due to the limited data available in the time of conducting this research.

CT protocols are used for two cases which have pulmonary metastases, as showed in Table 2, where CT is superior to MRI in soft tissue calcification, and this support the published result by Zimmer WD et al (14).

5. Conclusion

This retrospective study support that MRI protocols are superior in diagnosis of and osteosarcoma cases, and CT imaging is used as an aid in the cases with pulmonary metastases.

There are no published studies regarding this disease in Saudi society despite of the increasing of OS cases in the kingdom, and there is no public awareness of this type of tumor and how to care of OS young patients in the family. Therefore, we recommend more research, public awareness programs through all types of media to raise the public awareness regarding OS causes, diagnosis, and type of treatments.

6. References

- i. American Cancer Society. Cancer Facts & Figures 2016. Atlanta, Ga. American Cancer Society; 2016.
- ii. Kuchimaru, T., Hoshino, T., Aikawa, T., Yasuda, H., Kobayashi, T., Kadonosono, T. and Kizaka-Kondoh, S. (2014) 'Bone resorption facilitates osteoblastic bone metastasis by insulin-like growth factor and hypoxia. Von Kossa staining showing aberrant bone formation due to bone metastasis of murine osteosarcoma LM8 cells', *Cancer Science*, 105(5), p. May cover–May cover. doi: 10.1111/cas.12401.
- iii. Kaa, A.K.S., Jorgensen, P.H., Sojbjerg, J.O. and Johannsen, H.V. (2013) 'Reverse shoulder replacement after resection of the proximal humerus for bone tumours', *The Bone & Joint Journal*, 95-B(11), pp. 1551–1555. doi: 10.1302/0301-620x.95b11.31545.
- iv. Zwaga, T., Bovée, J.V.M.G. and Kroon, H.M. (2008) 'Osteosarcoma of the Femur with skip, lymph Node, and lung Metastases', *RadioGraphics*, 28(1), pp. 277–283. doi: 10.1148/rg.281075015.
- v. Printz, C. (2016) 'American cancer society reports on 25-year cancer mortality rate goals', *Cancer*, 122(15), pp. 2289–2291. doi: 10.1002/cncr.30175.
- vi. Stein-Wexler, R. (2011) 'Pediatric soft tissue Sarcomas', *Seminars in Ultrasound, CT and MRI*, 32(5), pp. 470–488. doi: 10.1053/j.sult.2011.03.006.
- vii. Groot, C.G. (1982) 'Electron microscopical x-ray microanalysis of mineralization nodules and several other tissue compartments in fetal bone', *Metabolic Bone Disease and Related Research*, 4(3), pp. 211–216.
- viii. Marcon, M., Keller, D., Wurnig, M.C., Weiger, M., Kenkel, D., Eberhardt, C., Eberli, D. and Boss, A. (2016) 'Separation of collagen-bound and porous bone-water longitudinal relaxation in mice using a segmented inversion recovery zero-echo-time sequence', *Magnetic Resonance in Medicine*.
- ix. KOZLOWSKI, K. and BUDZINSKA, A. (1966) 'COMBINED METAPHYSEAL AND EPIPHYSEAL DYSOSTOSIS', *American Journal of Roentgenology*.
- x. Picci P. Osteosarcoma (osteogenic sarcoma). *Orphanet J Rare Dis*. 2007 Jan 23. 2:6.
- xi. Wakabayashi H, Saito J, Taki J, Hashimoto N, Tsuchiya H, Gabata T, et al. Triple-phase contrast-enhanced MRI for the prediction of preoperative chemotherapeutic effect in patients with osteosarcoma: comparison with ^{99m}Tc-MIBI scintigraphy. *Skeletal Radiol*. 2015 Sep 18.
- xii. Dr Ibrahim mohammed al fawaz, Riyadh newspaper, bone tumor, 6-10-2010.